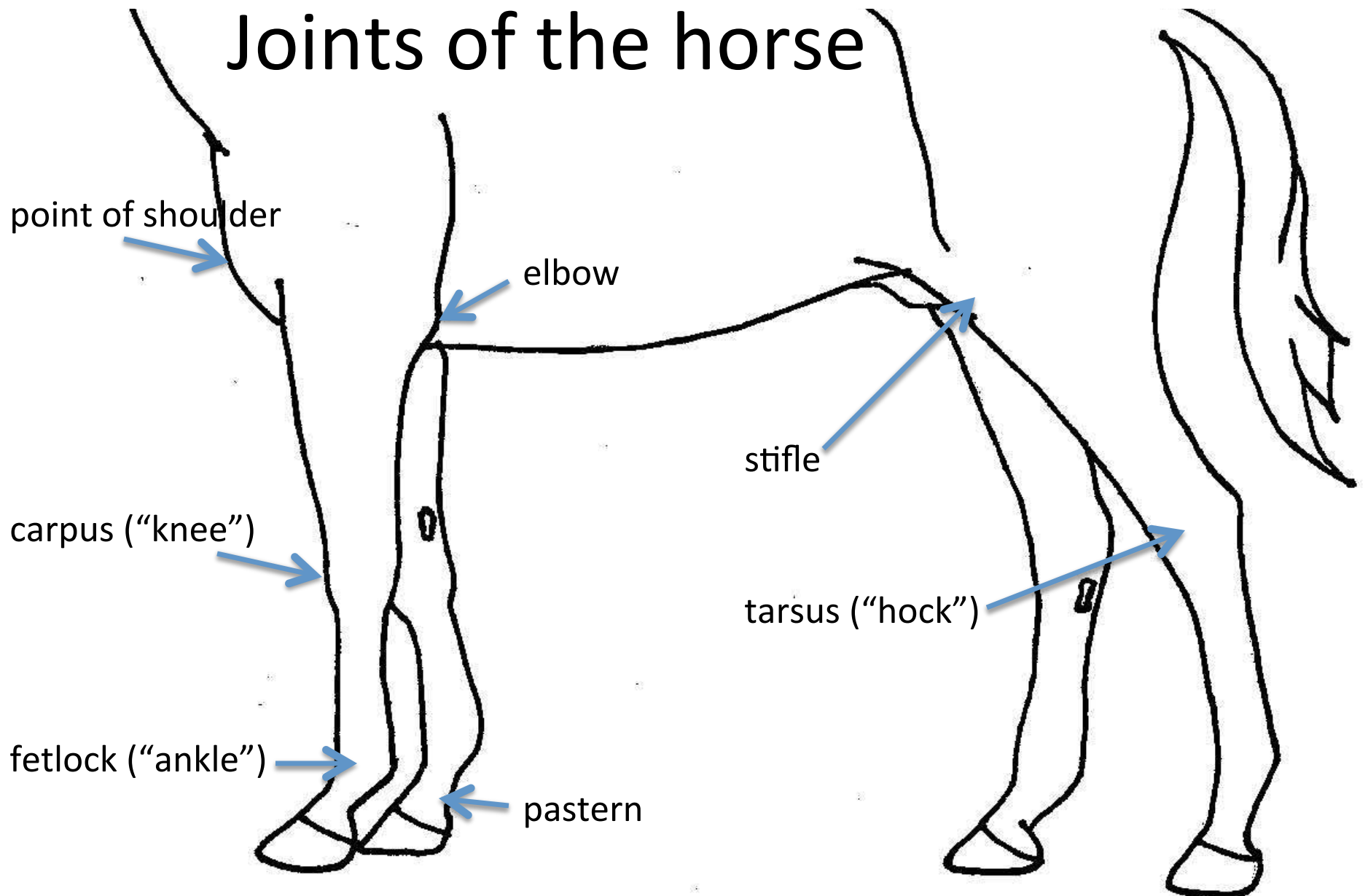


Childhood doodles...

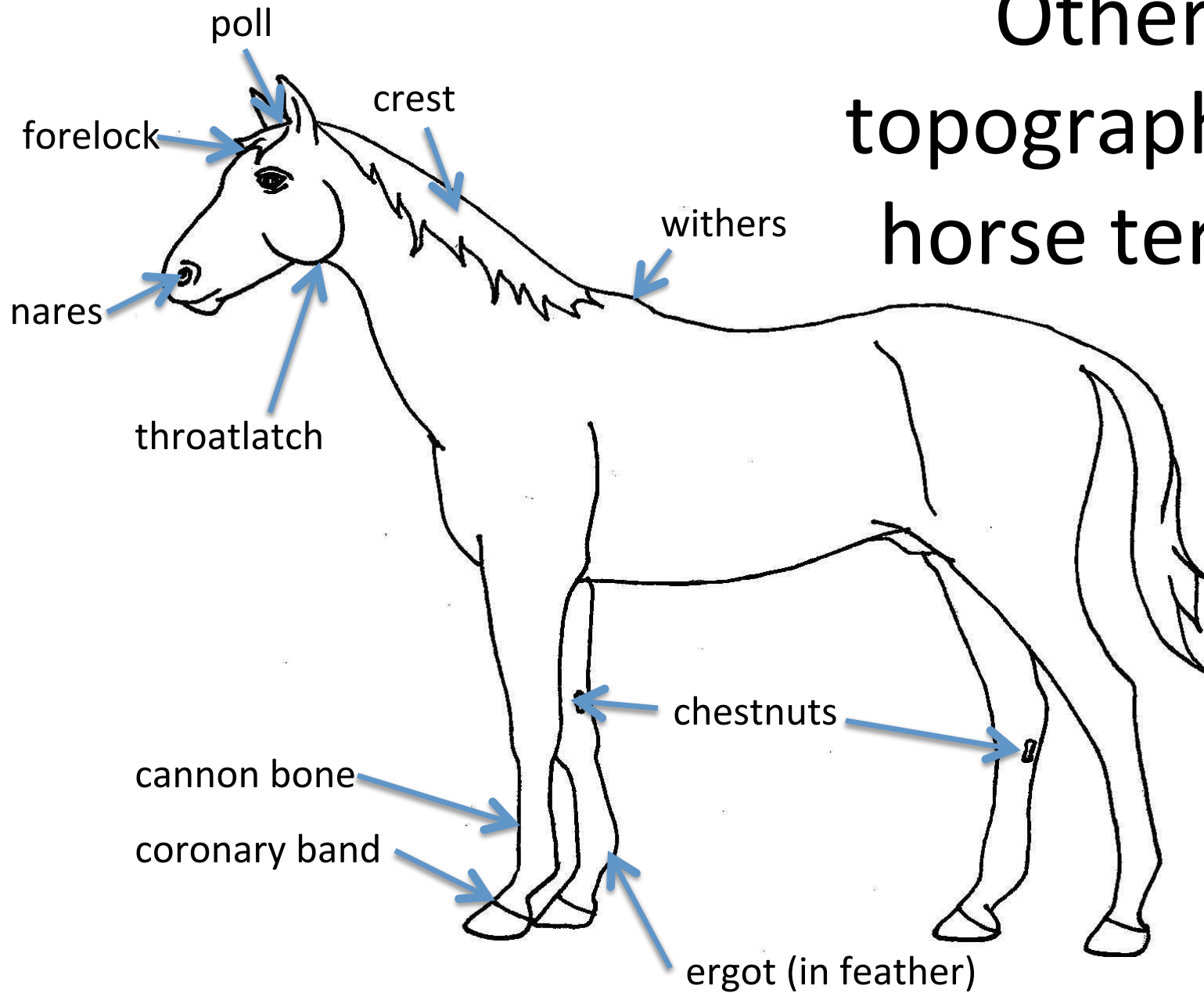
and some layman's anatomy terms!

Joanne Hewson, DVM, PhD, DACVIM
VETM 3430 Clinical Medicine I

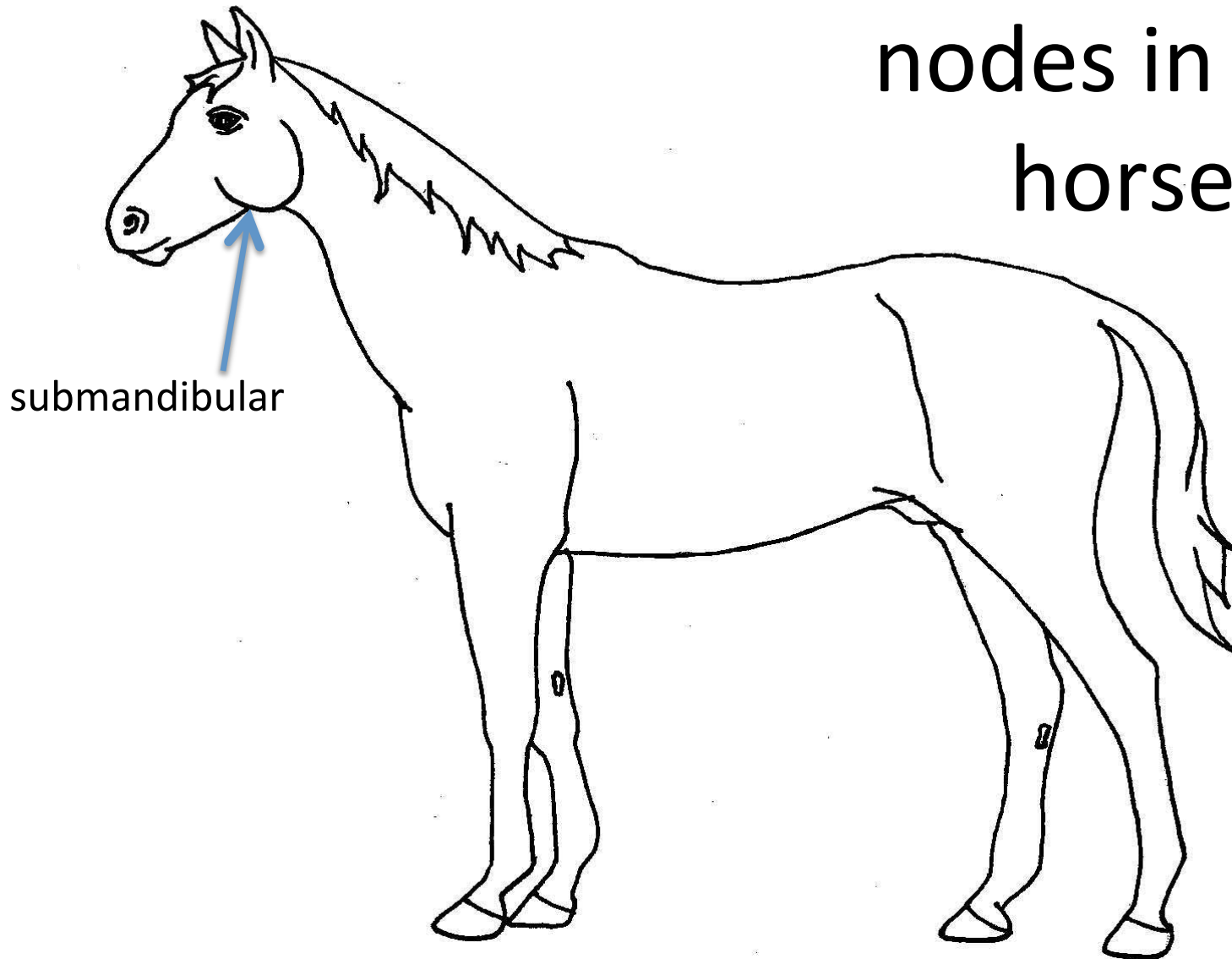
Joints of the horse



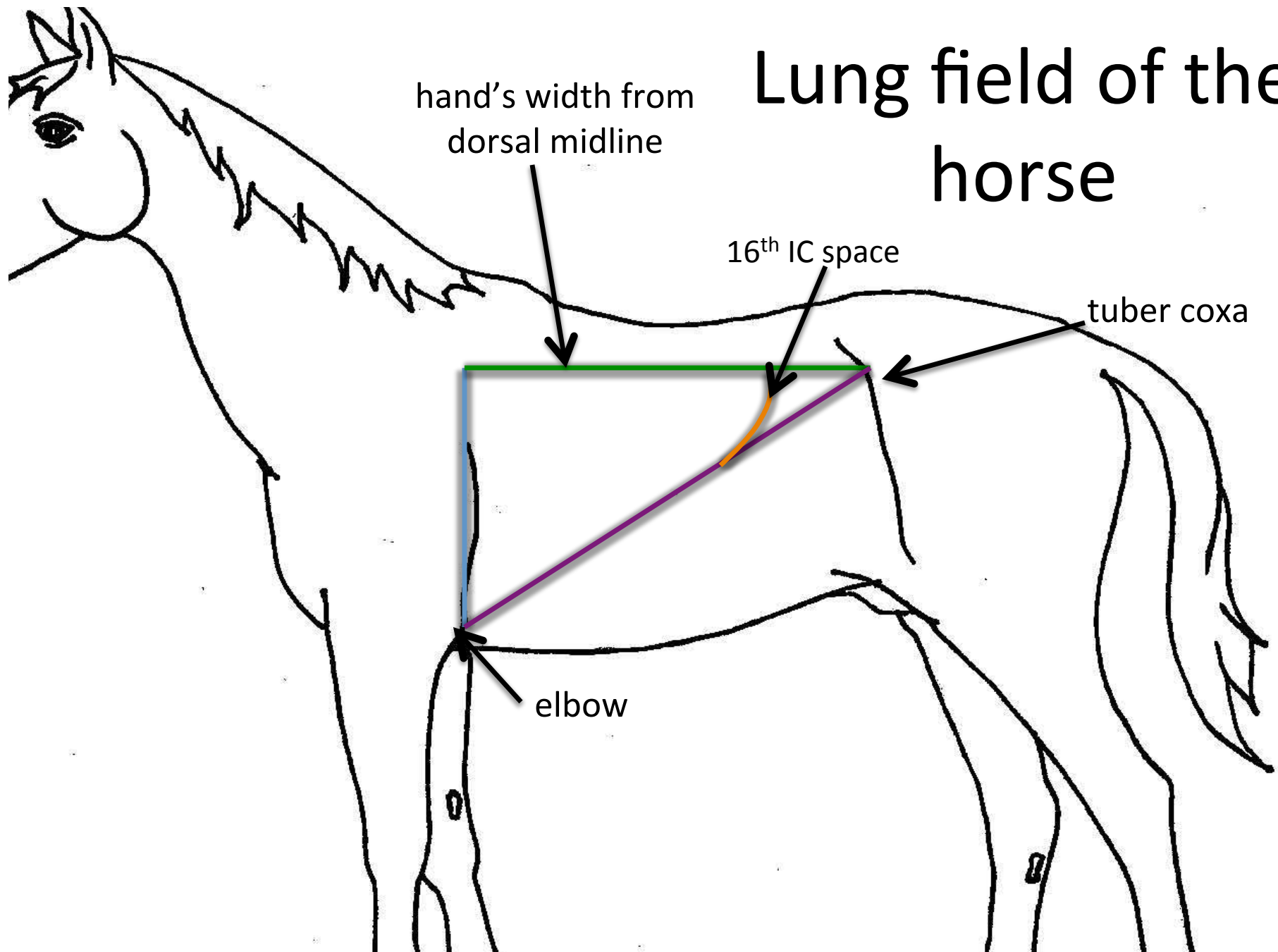
Other topographical horse terms



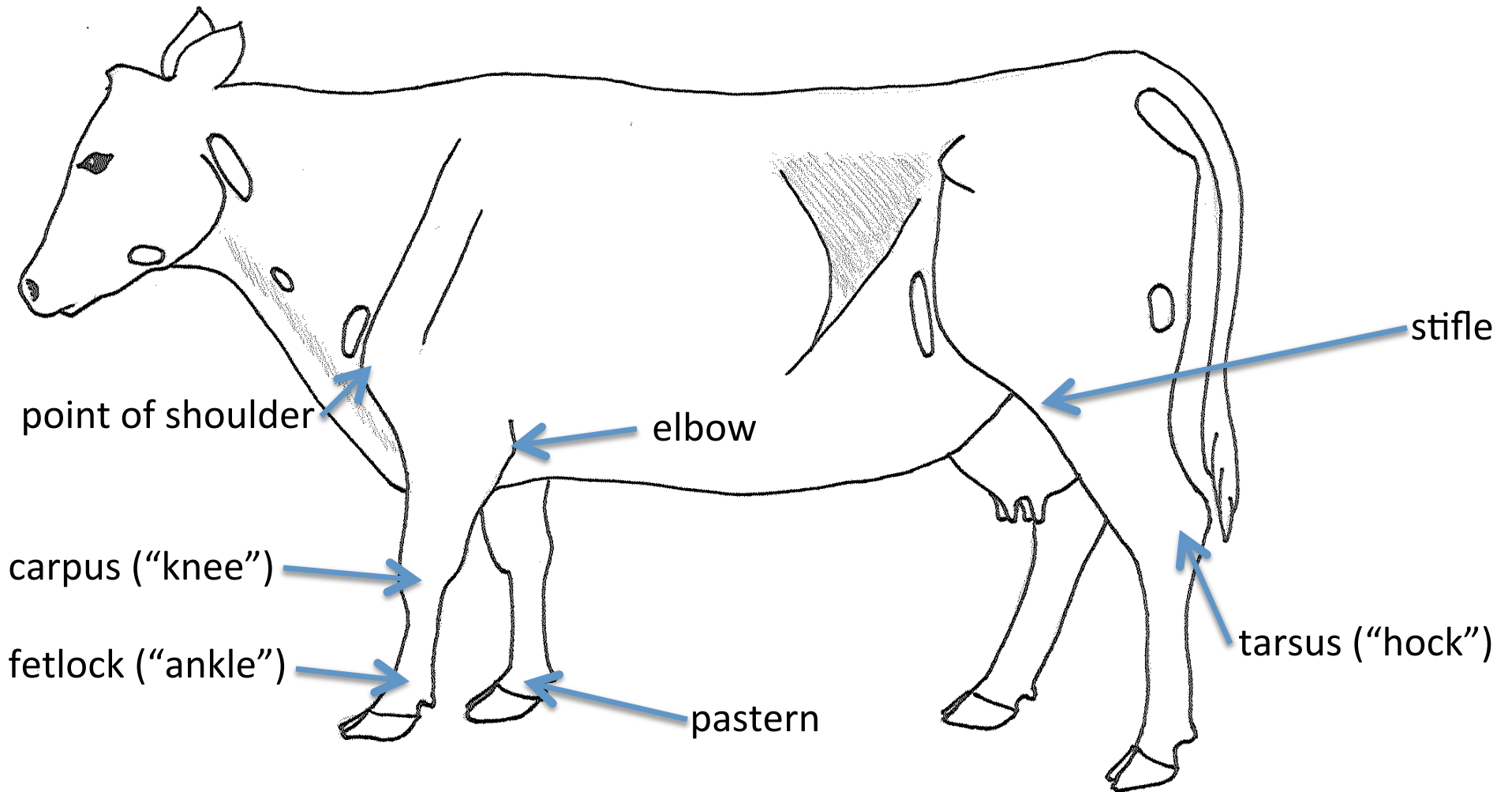
Palpable lymph nodes in the horse

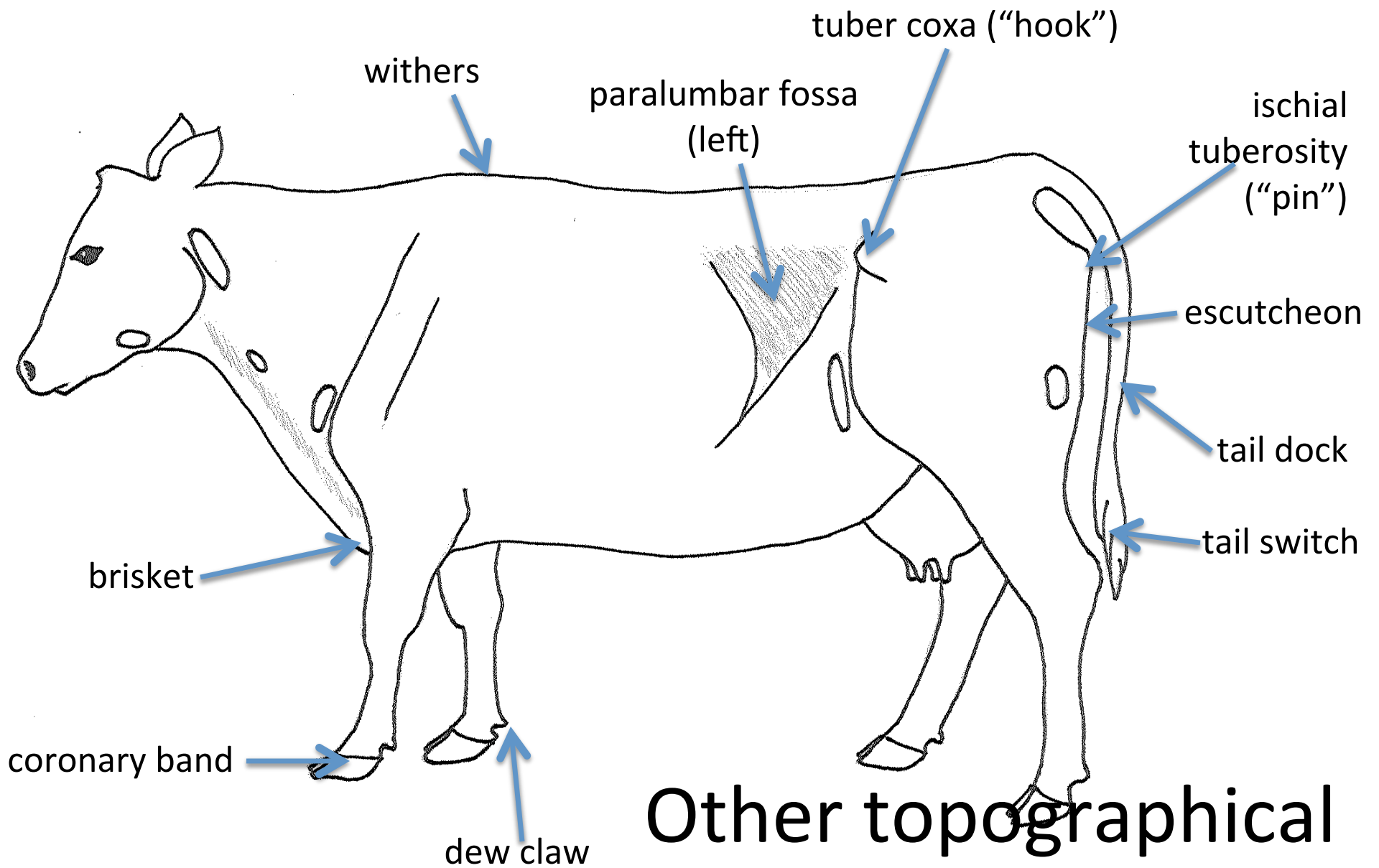


Lung field of the horse



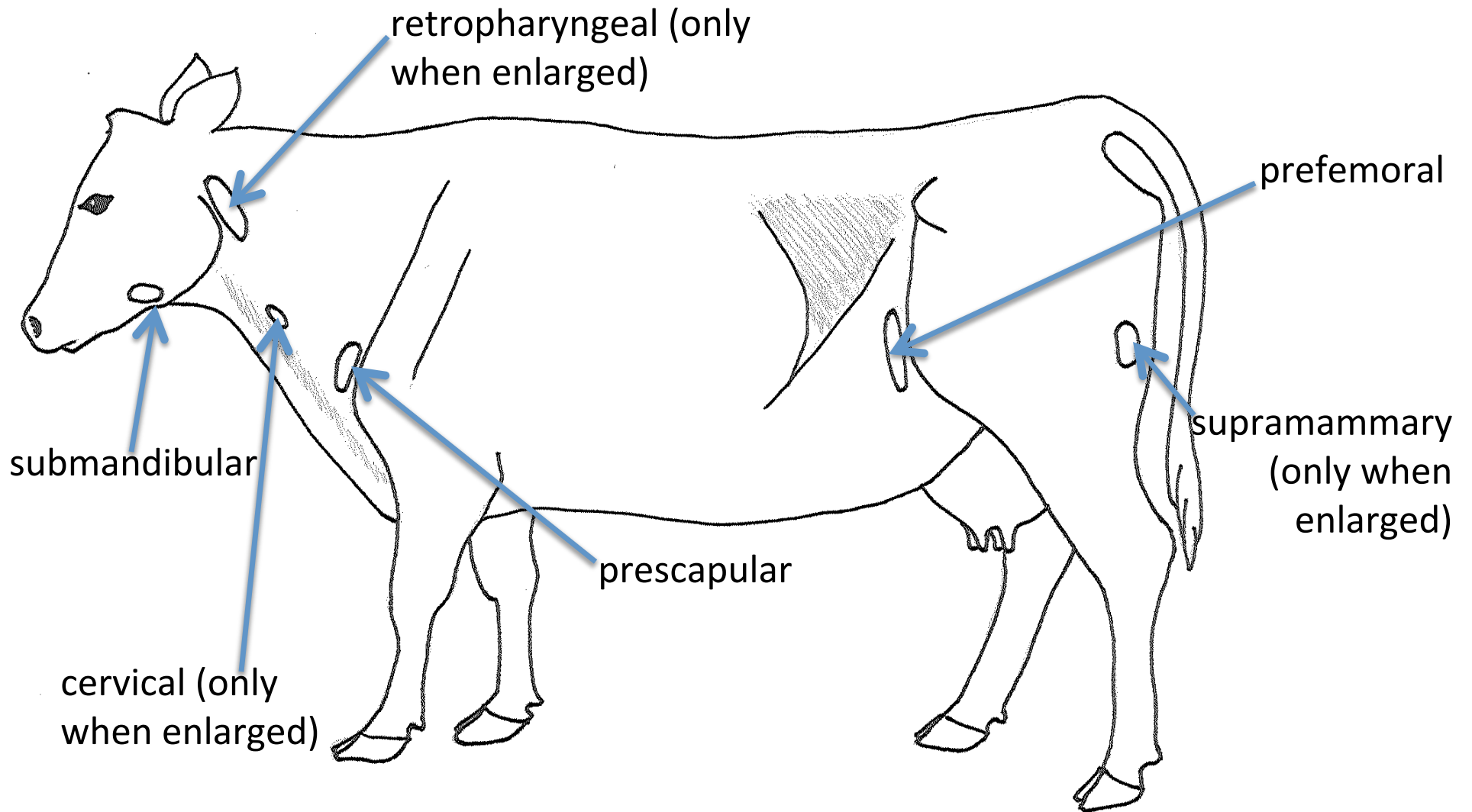
Joints of the cow





Other topographical
cow terms

Palpable lymph nodes in the cow



Lung field of the cow

